

Establishment of a Temporomandibular Physiological State with Neuromuscular Orthosis Treatment Affects Reduction of TMD Symptoms in 313 Patients

Barry C. Cooper, D.D.S.; Israel Kleinberg, Ph.D., D.D.S., D.Sc.

ABSTRACT: The objective of this investigation was to test the hypothesis that alteration of the occlusions of patients suffering from temporomandibular disorders (TMD) to one that is neuromuscularly, rather than anatomically based, would result in reduction or resolution of symptoms that characterize the TMD condition. This hypothesis was proven correct in the present study, where 313 patients with TMD symptoms were examined for neuromuscular dysfunction, using several electronic instruments before and after treatment intervention. Such instrumentation enabled electromyographic (EMG) measurement of the activities of the masticatory muscles during rest and in function, tracking and assessment of various movements of the mandible, and listening for noises made by the TMJ during movement of the mandible. Ultra low frequency and low amplitude, transcutaneous electrical neural stimulation (TENS) of the mandibular division of the trigeminal nerve (V) was used to relax the masticatory muscles and to facilitate location of a physiological rest position for the mandible. TENS also made it possible to select positions of the mandible that were most relaxed above and anterior to the rest position when the mandible was moved in an arc that began at rest position. Once identified, the neuromuscular occlusal position was recorded in the form of a bite registration, which was subsequently used to fabricate a removable mandibular orthotic appliance that could be worn continuously by the patient. Such a device facilitated retention and stabilization of the mandible in its new-found physiological position, which was confirmed by follow up testing. Three months of full-time appliance usage showed that the new therapeutic positions achieved remained intact and were associated with improved resting and functioning activities of the masticatory muscles. Patients reported overwhelming symptom relief, including reduction of headaches and other pain symptoms. Experts consider relief of symptoms as the *gold standard* for assessment of effectiveness of TMD treatment. It is evident that this outcome has been achieved in this study and that taking patients from a less to a more physiological state is an effective means for reducing or eliminating TMD symptoms, especially those related to pain, most notably, headaches.

0886-9634/2602-104\$05.00/0, THE JOURNAL OF CRANIOMANDIBULAR PRACTICE, Copyright © 2008 by CHROMA, Inc.

Manuscript received April 5, 2007; revised manuscript received January 10, 2008; accepted January 16, 2008

Address for correspondence: Dr. Barry Cooper
100 Harrison St.
Lawrence, NY 11559
E-mail: tmjccooper@aol.com

Dr. Barry C. Cooper received his D.D.S. degree in 1963 from Columbia University School of Dental and Oral Surgery. He is currently a clinical associate professor, Department of Oral Biology and Pathology of the State University of New York (SUNY) Stony Brook School of Dental Medicine. He has held faculty positions at Columbia University School of Dental and Oral Surgery, New York Medical College, and Temple University School of Dentistry. Dr. Cooper is past international president of the International College of CranioMandibular Orthopedics (ICCMO). He maintains a private practice in Hewlett and Manhattan, NY, limited to the treatment of patients with TMD.

The term temporomandibular disorder (TMD) is defined as a group of abnormal conditions involving the masticatory muscles, the temporomandibular joints, and the associated neurological and musculoskeletal structures.^{1,2} There are numerous published studies reporting on the significant prevalence of this disorder in population groups throughout the world³⁻¹⁰ and that pain is a major symptom. Relief of pain is a major reason why patients seek professional care.^{11,12} In the absence of a clear understanding of the causes of TMD, pain medications are extensively used to ameliorate this condition. This is only a stop-gap measure.

One theory proposed as the basis of TMD is that it is mainly the result of a dysfunctional masticatory system that is characterized by complicated interactions between various muscles, two temporomandibular joints, and a moveable mandible that supports a cadre of teeth that

engage in complex and intermittent interdigitations. It then follows that a desired goal of treatment is to identify and improve or correct any dysfunctions and correct the cause or causes of TMD and any related pain.

This would bring TMD study and treatment in line with what is well known in the muscle physiology and physiotherapy fields, namely, that muscles functioning under less than ideal conditions commonly result in compensating muscle activity, which needs to be corrected. Otherwise, deterioration can progress into a self-perpetuating chronic condition of increasing dysfunction and pain.

Over the last several decades, instrumentation has been developed to make it possible to objectively locate and establish what is commonly referred to as a patient's neuromuscular occlusion position. Neuromuscular occlusion is defined as a stable maxillomandibular position at occlusion arrived at by isotonic contraction of relaxed masticatory muscles. This is achieved by stimulation of muscles on a trajectory (arc) from a resting mandibular position. The instrumentation developed has enabled (1) measurement by surface electromyography (EMG) of masticatory muscle activity at rest and under a range of activations, such as clenching of the teeth; (2) tracking of the mandible where its movements and the electrical activity of associated muscles can be followed during jaw opening and closing, and during movement of the mandible forwards, backwards, and laterally as during eating; and (3) scrutinizing and recording sounds, if any, emanating from the temporomandibular joints during jaw movement using electrosonography.

Involved in the surface EMG measurements are the mandibular elevator and depressor muscles. The former includes the temporalis and masseters; the latter involves the digastrics. Recognized, at the same time, as an objective is the having of a strong and bilaterally symmetrical muscular closure of the mandible in preference to having one that is weak and asymmetrical.¹⁵⁻³¹

Mandibular tracking instrumentation is used to precisely record and analyze the speed, fluidity, and range of movements of the mandible. As in other skeletal muscular systems, smooth, fluid, and rapid movements made voluntarily are considered to be a more physiological condition than movements that are irregular (dyskinesic), slow (bradykinesic)³²⁻³⁴ and/or painful.

Electrosonography (ESG) enables the dental practitioner to listen to joint sounds during movements of the mandible. An ideal temporomandibular joint (TMJ) is one that is silent during such movements, whereas one where sounds are present suggests abnormalities within the joint complex.³⁵⁻⁴¹

The objective of this study was to determine:

(1) whether patients who presented with chronic symptoms of TMD could be objectively brought from a state of neuromuscular dysfunction to a state of neuromuscular function using the instrumentation mentioned above; (2) whether orthosis treatment can facilitate changing a non-physiological neuromuscular situation to one that is physiological; and (3) most importantly, whether such alterations result in relief and/or reduction in TMD symptoms, especially one as discomforting as pain.

The current study has tested these hypotheses by retrospective analysis of symptom data obtained in patients examined and treated for TMD in a clinical practice, where objective instrument methodology was used in conjunction with the wearing of orthotic devices to correct neuromuscular malocclusions, and thereby relieve TMD symptoms such as pain.

Materials and Methods

After obtaining a signed treatment consent form from each of more than 1500 patients seeking treatment in a dental office, each patient was asked to complete an in office self-evaluation questionnaire. This enabled assessment of the patient's symptoms and allowed an indication of how long they had them. Each patient was then subjected to a clinical signs examination performed by a single examining dentist. A presumptive diagnosis of TMD was made from the information obtained.

Criteria for inclusion of patients in the present analysis included presence of certain symptoms and signs recognized as characteristic of TMD.¹¹ There was no attempt to categorize the patients in a private practice reported in this study into TMD diagnostic subgroups. All patients, after initial screening, were assigned code numbers. From among those patients screened and subsequently tested and treated, 313 who showed complete data in all fields reported herein were subjected to analysis in this study. Many of the initially tested patients failed to return for follow-up re-evaluation testing, and their data therefore were not included in this study. The included 313 patients' data consisted of the following: (1) symptoms derived at baseline from a questionnaire; (2) signs obtained by oral examination immediately thereafter; (3) symptoms determined at one and three months by questionnaire as at baseline; and (4) neuromuscular examination information obtained at baseline and at the end of the analyzed treatment period. This consisted of EMG and jaw tracking measurements before and after transcutaneous electrical neural stimulation and sonography pre-TENS.

The subject population included 70 males and 243 females with a mean age of 40 for each group. The duration of each patient's TMD problem or problems was

determined at the same time. TMD symptomatology prior to baseline in 57% of the patients was between one and ten or more years. In 72% it was ≥ 6 months and in 21%, it was ≤ 3 months. It is therefore apparent that for these patients, their TMD were not self-limiting and had not resolved without therapeutic intervention or with other therapies.

After initial symptoms and signs were determined, patients were subjected to the following examinations. First, various mandibular and masticatory muscle levels of activity and function were measured and recorded. Electrosonography was performed. TENS was carried out in order to relax the masticatory muscles after electromyographic determination of the presenting resting state, i.e., when a muscle is at its lowest level of activity. After TENS, a second set of surface EMG and mandible tracking measurements were performed, which was followed by the taking of a maxillomandibular bite registration. Based on the findings, a removable oral orthotic device was designed and constructed (see below). In each case, devices covered the mandibular posterior teeth and the lingual surfaces of the mandibular anteriors. These were worn by each patient 24 hours a day, and for seven days a week over a period of three months. The appliance was removed by the patient only when doing daily oral hygiene. Patients were able to eat with the appliance in place, because it was designed with an anatomical occlusal surface.

EMG of Mandibular Elevator and Depressor Muscles

Electromyographic devices were used on the patients in this study (EM-2, K-6 EMG and K-7 EMG, Myotronics Noromed, Inc. Kent, WA) to collect baseline data, which consisted of bilateral EMG recordings of the main mandibular elevator and depressor muscles. The former included the anterior temporalis and the middle masseters; the latter included the anterior digastrics. The EMG device used permits simultaneous recording of four paired (bilateral) muscles. However, for this study only, three sets of muscles were monitored. Measurements were performed on each patient after he or she was instructed to assume a resting jaw position where the teeth are not touching. In each case, the patient was seated comfortably in an upright chair and instructed to sit with eyes slightly closed. Three successive sets of data were obtained and were then averaged. Data representing artifacts such as tooth contact or tongue movements during swallowing were discarded. After determining the resting muscle activity condition, maximum muscle activity was elicited by asking each patient to alternately clench his or her teeth maximally three times for two seconds, with two seconds of relaxation between each

clenching episode. This clenching exercise was repeated three times and the results were averaged.

Mandibular Tracking

Electronic devices (K-5, K-6I, K-7 Diagnostic Device, Myotronics Noromed, Inc., Kent, WA) were employed to locate and record the postural position of the mandible at rest relative to its position at maximum intercuspation. To facilitate relaxation of the mandibular elevator and depressor muscles, these were stimulated as above with a TENS device (Myomonitor, Myotronics, Noromed Inc. Kent, WA) for 60 minutes. The distance the mandible travels from its rest to its occlusion position (freeway space) and the trajectory of movement of the mandible in three dimensions (vertical, anterior/posterior and lateral) were subsequently determined. This included tracking of these mandibular movements by attaching a small 0.1 ounce magnet to the labial gingiva just below the lower incisors and following its movement electromagnetically. Note: all measurements were made at the incisor point (further details follow).

The TENS device delivers a low-frequency, low-voltage repetitive stimulus of approximately eight to 12 mA for 500 msec. It is powered by a nine volt battery and uses two active bilateral electrodes and a third grounding electrode placed in the center of the back of the neck. Repetitive stimuli were delivered at 1.5 sec intervals for a period of 60 minutes which resulted in rhythmic contractions of (1) the masticatory muscles which are innervated by the mandibular division of the trigeminal nerve (V) and (2) the facial muscles which are innervated by the superficial fibers of the facial nerve (VII).⁴²⁻⁴⁶

The mandibular division of the trigeminal nerve (V) is located deep to the mandible, which is stimulated superficially through the notch that exists between the coronoid and condylar processes of the mandible, i.e. anterior to the tragus of each ear. The facial nerve that traverses the area beneath the same surface electrode was also stimulated.

The threshold intensity of the TENS stimulus was established for each patient as the minimal amplitude necessary to activate the elevator muscles. This causes a rise in the patient's chin, resulting from each electrical stimulation. By the operator placing his index finger very lightly on the chin, it was possible to check the intensity of TENS stimulation and accordingly make adjustments during the hour of therapy, thereby avoiding over-stimulation. The TENS device can be adjusted by the operator to achieve bilateral balance of the magnitude of the stimuli induced muscle contractions that could be determined by manual palpation of the subject's cheeks.

After 60 minutes of TENS, EMG readings were made

to assess mandibular muscle electrical activity in the resting state, which ensured sufficient relaxation of the elevator and depressor muscles of the mandible. Again, three sets of measurements were obtained and averaged. Testing for clenching activity post-TENS was deferred until after a bite registration could be made. The delay was to avoid tiring of the relaxed closing muscles.

Mandibular tracking with contemporaneous EMG monitoring of resting muscle activity was then performed in order to locate in three dimensions, the new post-TENS rest position of the mandible relative to the patient's maximum intercuspal position. This served to identify a reference from which a therapeutic occlusal position could be selected and observed on the computer screen. This enabled intraoral recording in the bite registration material to be realized.

With a slight increase in the intensity of the TENS stimulus, the mandible was moved isotonicly on a neuromuscular trajectory (arc) from rest to its subsequent altered position which was recorded with the mandibular tracking instrument. A point one mm above the TENS-induced and electromyographically monitored rest position of the mandible was identified on the TENS stimulated trajectory, which became the neuromuscular occlusion, treatment position.

Neuromuscular Bite Registration

An intraoral registration of the neuromuscular occlusal position was made with a soft, low-resistance acrylic impression material (Bosworth Sapphire, H.J. Bosworth Co., Skokie, IL). The bite registration was removed from the mouth in its rubbery, partially cured state. Excess buccal and lingual acrylic material was removed with scissors. The bite registration was then carefully transferred to lubricated maxillary and mandibular study casts for complete curing. Care was taken not to compress the bite registration between the two casts. Any excess registration material was trimmed away to permit clear visualization of the complete seating of study casts into the bite registration. Careful trimming of the bite registration prevents fracture of the stone cast that can occur upon removal of the hardened registration material after its complete curing.

Once cured, the hard acrylic bite registration was removed from the casts and returned to the patient's mouth for mandibular tracking and verification of the accuracy of the neuromuscular position recorded. Improvement of the bilateral clench function was also checked using EMG. The bite registration was then sent to the dental laboratory together with the dental casts mounted on a Terminus Articulator (Myotronics Noromed, Inc. Kent, WA) for the fabrication of a ther-

apeutic mandibular orthotic appliance. The natural occlusion and the articulated neuromuscular maxillomandibular relationship with the bite registration are shown in **Figures 1** and **2**, respectively.

Mandibular Orthotic Appliance Fabrication and Use

The removable mandibular orthotic appliance constructed for each patient was made of either clear acrylic or of a tooth-colored acetal resin material (DurAcetal, Cosmetic Dental Materials, Albany, OR). The occlusal surface of the device was designed to provide a stable maxillomandibular therapeutic occlusal relationship. In doing so, the occlusion was set 1-2 mm above and anterior to the EMG monitored mandibular rest position along the TENS stimulated trajectory (arc) of mandibular movement that begins at the rest position of the mandible. As indicated by EMG measurements, rest position is identified as an equilibrium position where there is minimal electrical activity in the antagonistic mandibular

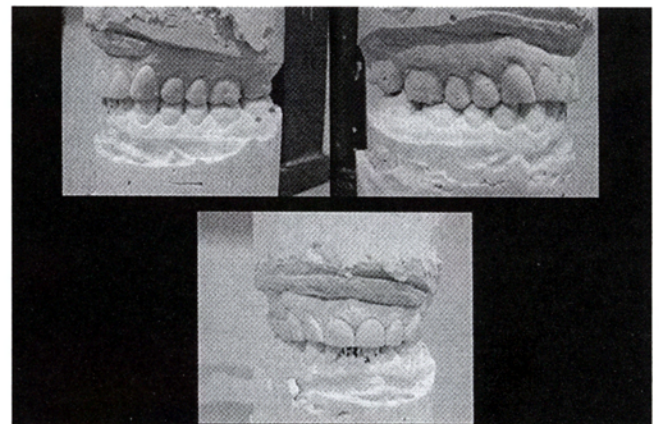


Figure 1
Study casts in natural occlusal relationship: referred to as centric occlusion (CO), maximum intercuspation (MIP), or intercuspal position (ICP).

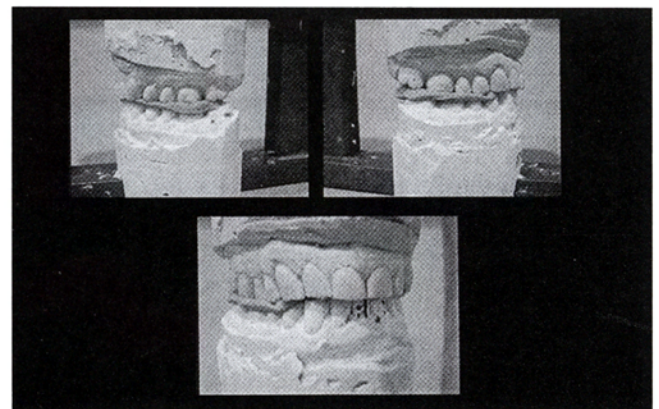


Figure 2
Articulated study casts with bite registration in neuromuscular relationship.

elevator and depressor muscles. The neuromuscular occlusion, thus determined, is stable. The surface morphology of the orthotic device includes mandibular cusps and fossae positioned to occlude with opposing maxillary fossae and cusps. The neuromuscular orthosis is shown on articulated models and intraorally in **Figures 3** and **4**, respectively.

To ensure maximum neuromuscular and bilateral symmetrical function while clenching, the final adjusted occlusion provided by the orthotic appliance was re-tested using EMG.

Each patient wore his or her oral appliance for 24 hours a day, seven days a week for three months. Then, a complete EMG testing was performed in which the baseline data collection protocol was followed with some modifications. Data were then obtained for muscle activities during rest and clenching with the appliance positioned on the mandibular teeth and when the cured acrylic bite registration obtained at the initial test visit was similarly

tested. Maximum voluntary clenching with nothing between the teeth was not tested at the three month retesting visit, since patients had become adapted to closing on the orthotic device.

The accuracy and coincidence of the therapeutic occlusal position provided by the orthotic appliance and by the bite registration with the TENS stimulated arc of jaw movement were also tested with the mandibular tracking device at the three-month test visit. Any inaccuracies were noted.

Before bedtime, a neutral sodium fluoride brush-on gel was prescribed for use after regular tooth brushing but without rinsing in order to favor greater fluoride uptake and increased caries resistance.

Data Analysis and Statistical Methods

All test data were entered into a computerized database using a Microsoft Visual FoxPro program, especially created for this ongoing clinical study. Student's t-test was utilized to determine statistical significance. EMG activity during rest, before and after TENS, was compared before and after three months treatment, as was EMG maximum clench activity. Included was the baseline occlusion position, the treatment occlusal position with the bite registration inserted, and the position where the orthotic appliance was in place. Statistical comparisons of the EMG resting muscular activity (involving middle masseter, anterior temporalis and anterior digastric muscles) and maximum clench activities (involving the masseter and temporalis muscles) were performed. Occlusal positions at presentation and in the therapeutically corrected neuromuscular position were compared and statistically analyzed. Using the Student's t-test, data paired comparisons were made of identical (matched pairs) patient groups, before and after therapeutic interventions to determine the level of significance (confidence) of the differences recorded.

Results

The age and gender distribution of the subjects in this study are shown in **Figure 5**. More females than males made up the patient population studied. This may reflect a sex prevalence difference and has been reported in many studies including one comprised of 4,528 patients presenting to a dentist for TMD evaluation and possible treatment.¹¹

Symptoms Identified and Ameliorated

The symptom results obtained from the questionnaire are shown in **Table 1**. This shows a dramatic reduction in the incidence of headaches by one month and further

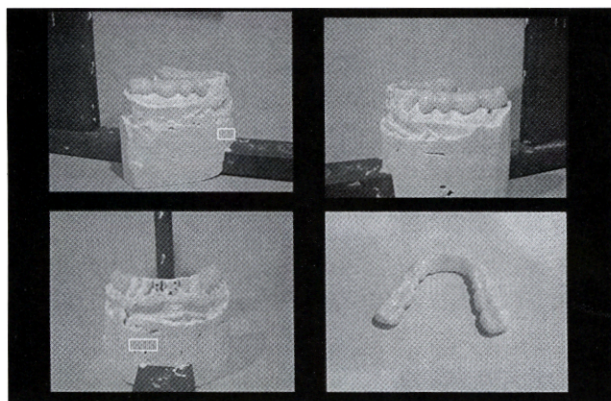


Figure 3
Acetal resin neuromuscular mandibular orthosis. Note: Occlusal plane of anterior teeth is continued with occlusal plane of orthosis.

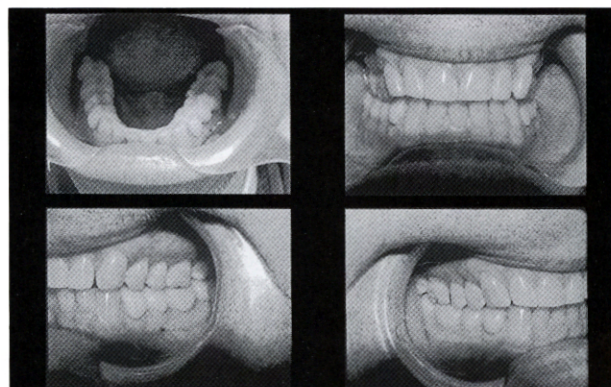


Figure 4
Intraoral view of the neuromuscular mandibular orthosis. Occlusal anatomical form of mandibular appliance interdigitates with maxillary teeth providing stable occlusion.

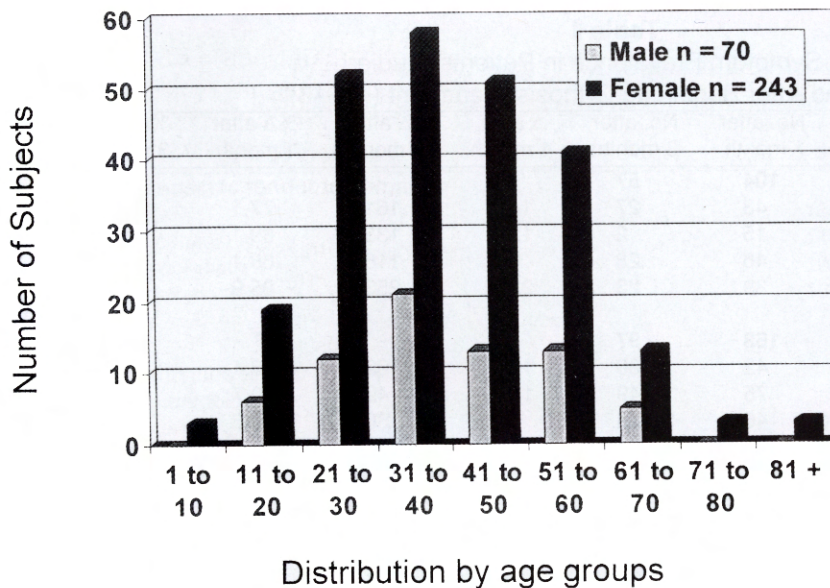


Figure 5
Age and gender distribution of the patients studied (n=313).

improvement at three months. Of the 313 study subjects, 276 initially reported headaches. But, at one month, subjects with headaches decreased to 76 and to 37 at three months (i.e., 75.7% and 80.8% reductions, respectively). Similar large improvements or cures were observed for TMJ, ear, facial, cervical and back pain symptoms at one and three months, respectively (**Table 1**). It was evident that the total number of symptoms for the total subject population and the number of symptoms per patient decreased dramatically following the diagnoses and treatments that were performed herein (**Table 1**).

The average number of symptoms per patient fell from 7.7 to 2.4 in one month (68.8% reduction from baseline) and to 1.5 at three months (80.5% reduction from baseline), suggesting overall that a much healthier state was achieved (**Table 1**).

The prevalence of various TMD clinical examination findings (signs) in the study population determined at baseline before orthosis treatment is presented in **Table 2**.

Electrical Activity of Muscles at Rest

At baseline, where the EMG activities of the main elevator (anterior temporalis and middle masseter) and depressor (anterior digastric) muscles were elevated at rest, reduction in these activities after TENS was clearly evident as shown in **Figure 6**. After three months of orthosis treatment, the resting electrical activities recorded before TENS treatment in these muscles were lower than

their resting activities before TENS at initial baseline testing (**Table 3**).

Most interesting was that EMG activities were similar after baseline TENS, as those recorded after TENS administered following three months of orthosis treatment. This suggests that a true resting muscle EMG level was identified and achieved.

At baseline, the mean resting EMG activity for the combined bilateral activity of the temporalis, masseter, and digastric muscles (using the greater of left vs. right muscles for respective muscle groups in each patient) was 4.3 ± 0.4 μ volts. After 60 minutes of TENS, the mean activity of all three of these muscles was reduced to 3.0 ± 0.6 μ volts. The decrease was highly significant ($p < 0.001$). After three months of full time orthosis treatment, the same measurement of EMG resting activity in the three sets of muscles before TENS was 3.3 ± 0.3 μ volts. After 60 minutes of TENS, this decreased to 2.7 ± 0.4 μ volts. The differences were again statistically highly significant (**Table 3**; $p < 0.001$).

EMG Activity in the Temporalis and Masseter Muscles After Activation by Clenching

At baseline testing, bilateral recordings (using the greater of left vs. right) during maximum clenching of the natural dentition, averaged 90.1 ± 5.2 μ volts for the temporalis and 87.4 ± 6.3 μ volts for the masseter muscles. After 60 minutes of TENS, when the acrylic bite registration in the neuromuscular occlusion position was obtained

Table 1
TMD Symptom Prevalence in Patients Studied
Before and After Beginning Orthosis Treatment (n=313)

| Symptom | No. at baseline | No. after 1 month | No. after 3 months | Δ after 1 month | Δ after 3 months | %Δ after 1 month | %Δ after 3 months |
|--------------------------------|-----------------|-------------------|--------------------|-----------------|------------------|------------------|-------------------|
| Headache | 469 | 104 | 57 | | | | |
| Temple | 188 | 43 | 27 | 145 | 161 | 77.1 | 85.6 |
| Frontal | 137 | 15 | 2 | 122 | 135 | 89.1 | 97.8 |
| Occipital | 144 | 46 | 28 | 98 | 116 | 68.1 | 80.6 |
| Any headaches | 276 | 39 | 23 | 237 | 253 | 85.9 | 91.7 |
| TMJ | 489 | 163 | 97 | | | | |
| Pain in joint | 192 | 42 | 30 | 150 | 162 | 78.1 | 84.4 |
| Joint sounds | 191 | 75 | 49 | 116 | 142 | 60.7 | 74.4 |
| Limited joint opening | 106 | 46 | 18 | 60 | 88 | 56.6 | 80.0 |
| Any joint symptoms | 269 | 49 | 32 | 220 | 237 | 81.8 | 88.1 |
| Ear symptoms | 519 | 157 | 99 | | | | |
| Otalgia (no infection) | 161 | 34 | 19 | 127 | 142 | 78.9 | 88.2 |
| Tinnitus | 124 | 44 | 36 | 80 | 88 | 64.5 | 71.0 |
| Dizziness | 117 | 37 | 21 | 80 | 96 | 68.4 | 82.1 |
| Muffled ears | 117 | 42 | 23 | 75 | 94 | 64.1 | 80.3 |
| Any ear symptoms | 258 | 43 | 22 | 215 | 236 | 83.3 | 91.5 |
| Other symptoms | 919 | 313 | 201 | | | | |
| Facial pain | 146 | 30 | 23 | 116 | 123 | 79.5 | 84.3 |
| Cervical pain | 178 | 59 | 42 | 119 | 136 | 68.9 | 76.4 |
| Back pain | 140 | 60 | 47 | 80 | 93 | 57.1 | 66.4 |
| Throat symptoms | 135 | 57 | 22 | 78 | 113 | 57.8 | 83.7 |
| Uncomfortable bite | 118 | 46 | 26 | 77 | 92 | 65.3 | 78.0 |
| Pain behind eyes | 125 | 44 | 26 | 81 | 99 | 64.8 | 79.2 |
| Tooth pain | 77 | 17 | 15 | 60 | 62 | 77.9 | 80.5 |
| Total symptoms | 2,396 | 737 | 454 | | | | |
| Mean # of symptoms per patient | 7.7 | 2.4 | 1.5 | 5.3 | 6.2 | 68.8% | 80.5% |

Note: Total number of subjects who experienced some symptom improvement or were cured: after 1 month=308 (98.4%); after 3 months=310 (99.04%)

and tested, EMG activity with maximum muscle clenching on the bite registration device was significantly elevated to 136.7±5.9 μvolts for the temporalis and 160.6±7.1 μvolts for the masseter muscles (Table 4). The alteration in clench function of the temporalis and masseter muscles was once more highly statistically significant (p<0.001) (Table 4, Figure 7).

Interestingly, a shift in dominance at the initial baseline test changed from the temporalis muscles in the natural occlusion position to the masseter muscles in the neuromuscular bite occlusal position. The anatomical direction of force of the temporalis muscle is upwards and backwards, while the masseter is upwards and forwards. The latter is the trajectory of TENS stimulated jaw

movement that is used to obtain the neuromuscular bite registration and reflects the natural swing path of the jaw. The shift from temporalis to masseter dominance observed reflects this improved therapeutic functional direction of jaw movement from rest to occlusion.

After three months of mandibular orthotic appliance usage, the maximum clench activity before TENS on the orthosis appliance recorded 101.3±5.6 μvolts for the temporalis muscles (using the greater of left vs. right for each subject). This was notably higher compared to baseline as was the value of 116.1±7.2 μvolts for the masseter when compared to its baseline reading. After 60 minutes of TENS therapy, maximum clench activity was tested using the same bite registration that had been obtained at

Table 2
Prevalence of Various TMD Signs in the Study Subjects
Determined at Baseline Before Orthosis Treatment (n=313)

| | Prevalence (no. of subjects) | Prevalence (% of subjects) |
|--|---------------------------------|-------------------------------|
| Extraoral muscles tender to palpation | | |
| Temporalis | 188 | 60.1 |
| Posterior cervical | 115 | 36.7 |
| Sternocleidomastoid | 102 | 32.6 |
| Angle of the mandible | 168 | 53.7 |
| Trapezius | 70 | 22.4 |
| Intraoral muscles tender to palpation | | |
| External pterygoid | 287 | 91.7 |
| Internal pterygoid | 223 | 71.3 |
| Masseter | 24 | 7.7 |
| Other clinical signs | | |
| Pain on TMJ palpation (with or without jaw movement) | 209 | 66.8 |
| Pain on ear palpation | 145 | 46.3 |
| Palpable condylar heads | 196 | 62.6 |
| TMJ sounds with stethoscope | 113 | 36.1 |
| Limited opening (<35 mm interincisal) | 64 | 20.5 |
| Lateral deviation (opening or closing) | 126 | 40.3 |
| Slow or staggered movement (open/close) | 144 | 46.0 |
| Dental findings* | 202 | 64.5 |

*Any of the following: worn incisal edges, missing posterior bite, bi-level occlusion, deep overbite, severe overjet, midline discrepancy.

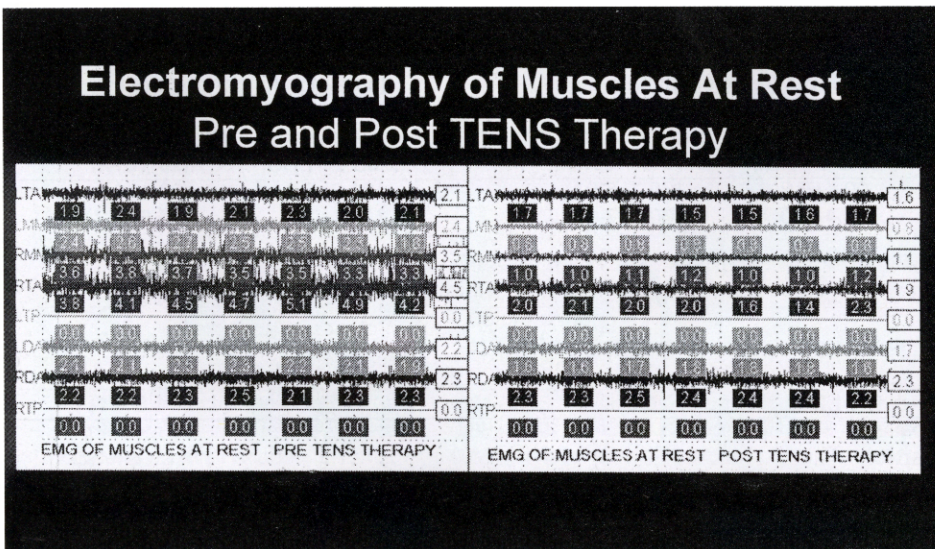


Figure 6
EMG comparison of selected masticatory muscles at rest at presentation, pre-TENS therapy where electrical activity is elevated (left). After TENS therapy resting electrical activity is significantly reduced (right).
LTA and RTA=left and right anterior temporalis;
LMA and RMA=left and right middle masseter;
LDA and RDA=left and right anterior digastrics;
LTP and RTP channels were not tested in this study.

Table 3
Average EMG Values in Micro-Volts (\pm SE) of Several TMD Related Muscles Measured at Rest Before and After TENS-Induced Muscle Relaxation Before and After Three Months of Orthosis Treatment (n=313)

| Muscles measured* | Before orthosis treatment at baseline | | After three months orthosis treatment at retest | |
|--------------------------------|---------------------------------------|---------------|---|---------------|
| | Before TENS | After TENS | Before TENS | After TENS |
| Temporalis anterior | 3.4 \pm 0.2 | 2.4 \pm 0.5 | 2.7 \pm 0.2 | 2.1 \pm 0.3 |
| Middle masseter | 2.4 \pm 0.2 | 1.5 \pm 0.1 | 2.1 \pm 0.1 | 1.3 \pm 0.1 |
| Digastric anterior | 2.9 \pm 0.4 | 2.1 \pm 0.3 | 2.4 \pm 0.3 | 2.0 \pm 0.3 |
| All six left and right muscles | 4.3 \pm 0.4 | 3.0 \pm 0.6 | 3.3 \pm 0.3 | 2.7 \pm 0.4 |

*Greater left vs. right muscle values for each patient.

the baseline test visit. It was inserted between upper and lower teeth instead of the mandibular orthosis. This demonstrated further elevated functional activity for all muscles with average recordings for the temporalis being 133 \pm 6.1 μ volts and for the masseter muscles being 159.6 \pm 7.2 μ volts, ($p < 0.001$) for both comparisons.

These data are similar to values for the same bite registrations tested at baseline. The change in temporalis muscle activity between the clench into the orthotic device (pre-TENS) and the clench into the bite registra-

tion device (post-TENS) represents an increase in electrical activity in the temporalis and masseter muscles. Also observed was a perpetuation of masseter over temporalis dominance over that of the temporalis as demonstrated previously at baseline. Both occlusal positions tested after three months of orthosis treatment (orthosis and bite registration) represent therapeutic interventions.

Maximum clenching activity for the natural dentition was not tested at retest in either the pre-TENS or post-TENS protocol because subjects had adapted to the full

Table 4
Average EMG Values in Micro-Volts (\pm SE) of Muscle Activity During Maximum Clench on Natural vs. Therapeutic Occlusion Before and After Three Months of Orthosis Treatment (n=313)

| Muscles measured | Clench EMG values before orthosis treatment at baseline | | Clench EMG values after three months orthosis treatment | |
|--------------------------|---|----------------------------|---|----------------------------|
| | Teeth to teeth | Teeth to bite registration | Teeth to orthosis | Teeth to bite registration |
| | Before TENS | After TENS | Before TENS | After TENS |
| Temporalis anterior* | 90.1 \pm 5.2 | 136.7 \pm 5.9 | 101.3 \pm 5.6 | 133.1 \pm 6.1 |
| Middle masseter* | 87.4 \pm 6.3 | 160.6 \pm 7.1 | 116.1 \pm 7.2 | 159.6 \pm 7.2 |
| % subjects where TA>MM** | 56.9% | 32.4% | 39.9% | 28.9% |
| % subjects where MM>TA** | 41.9% | 66.8% | 57.4% | 69.6% |
| % subjects where TA=MM** | 1.2% | 0.8% | 2.7% | 1.5% |

*Greater of left vs. right for each patient

**Average of left and right

TA: temporalis anterior; MM: masseter middle

Electromyography Comparison of Muscle Function = Clench

Natural teeth v. Neuromuscular myobite

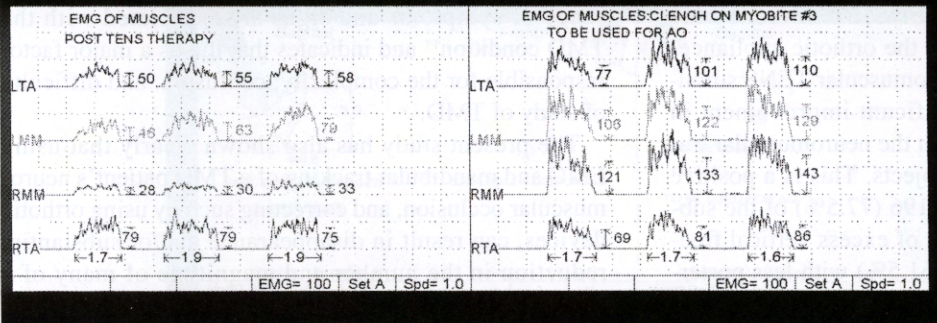


Figure 7

EMG comparison of muscles in function during maximum voluntary clench after TENS muscle relaxation therapy. Clench on natural dentition (left) shows weak asymmetrical function. Clench on acrylic bite registration in neuromuscular position (right) shows stronger, more symmetrical activity with masseter dominance over temporalis. Bite registration used to fabricate acetal resin orthosis (AO).

time presence of an oral orthotic device in their mouths by the end of the three month treatment period. Even though the appliance lost some of its anatomical details during the three months because of attrition, the Blue Sapphire bite registration obtained at the initial visit was unchanged from that tested at baseline (Table 4). This made it possible to compare the function and accuracy of the neuromuscular occlusion of the orthotic appliance after three months of usage to that recorded at baseline.

Mandibular Tracking

Tracking of the movements of the mandible electronically enabled recordings to be made of the movement of the mandible in millimeters from its rest to its occlusion position at the incisal point and the ability to display these movements as separate vectors, viz. vertical, anterior/posterior and lateral. It was also possible to display sagittal and frontal recordings of the same mandibular movement trajectories from rest to occlusion as well.

Freeway Space Analysis

Average vertical freeway space measured at the incisor point anteriorly increased from 1.81 to 3.44 mm after TENS therapy at the initial baseline testing. A smaller change in vertical freeway space was observed after three months between pre-TENS (1.33 mm) and after-TENS (1.75 mm) compared to the change in resting freeway space observed at baseline. This was because the corrective orthosis was put in place over the mandibular teeth at the three month test, which corrected for excess freeway space between the natural teeth⁴⁷⁻⁵⁴ ($p < 0.001$, Table 5).

Another test of these same parameters was performed for a subgroup of these patients undergoing long-term treatment and was used to validate the accuracy of the bite registration used in the long-term treatment process. These data are not reported in the present study.

Trajectory Analysis

At baseline testing, only 49 patients (15.9% of the test population) had occlusions that were coincident with the TENS stimulated neuromuscular trajectory. In addition,

Table 5
Mean Freeway Space in mm Between Rest and Occlusal Positions Determined by Mandibular Tracking Recorded at Mandibular incisors (n=313)

| | Before orthosis treatment at baseline (natural teeth) | | After orthosis treatment at three month retest (w/orthosis) | |
|----------------------------------|---|------------|---|------------|
| | Before TENS | After TENS | Before TENS | After TENS |
| Vertical freeway space | 1.81±0.15 | 3.44±0.11 | 1.33±0.09 | 1.75±0.09 |
| Anterior/posterior freeway space | 0.88±0.90 | 1.46±0.11 | 0.74±0.07 | 0.90±0.09 |
| Lateral freeway space | 0.36±0.04 | 0.61±0.06 | 0.32±0.03 | 0.38±0.05 |

253 (82.1%) of the patients had over-closures (excess vertical freeway space >2.0 mm), 221 (71.8%) had posterior mandibular displacements and 166 (53.9%) had lateral displacements (Table 6, Figure 8).

After three months of orthosis treatment, when the trajectory of movement (after TENS) from rest to the occlusal position (facilitated by the orthotic appliance) was analyzed relative to the neuromuscular TENS stimulated occlusal position, a significant improvement in coincidence of the occlusion with the neuromuscular trajectory was observed in 140 subjects. This is a positive treatment outcome. There were 196 (77.5%) of the subjects with less negative findings of excess vertical freeway space (over closure), 136 (61.5%) with less posterior displacement, and 114 (68.7%) with less lateral displacements. These too are positive treatment outcomes (Table 6).

Oral appliances in full-time use undergo some attrition and lose some occlusal anatomical form and accuracy that is peculiar to each patient. Because of this, in addition to simultaneous remodeling of muscle, joint and vascular supply during the treatment period, some inaccuracy in the occlusal position of the appliance resulted and became evident at the time of retesting. This was observed by comparing the data obtained with the orthosis in place to that observed testing with the original acrylic bite registration.

Discussion

The findings in this study have clearly demonstrated that there is a physical dysfunctional basis for TMD, which can be corrected by establishing a neuromuscular

occlusion and the use of an oral orthosis that provides this corrected occlusion. A drastic reduction of many of the symptoms associated with TMD was observed. Most importantly, this finding confirmed the conclusion drawn by the authors in an earlier extensive survey that a wide range of symptoms and signs are associated with the TMD condition¹¹ and indicates that this is a major factor responsible for the complexity, confusion, and difficulty of study of TMD.

The present study has also shown clearly that using EMG and mandibular tracking of a TMD patient's neuromuscular occlusion, and correcting such by using orthotic devices, can result in disappearance and/or substantial reduction in the number and magnitude of many of a TMD patient's symptoms. This includes headaches, which in this study resulted in a 91.7% reduction in their prevalence at three months. The significance is that these results support the view that most patients seeking relief from headaches and other painful symptoms are not doing so for psychological, but rather for physiological reasons.

Besides demonstrating that the patients in this study can be effectively and objectively treated, the data demonstrate that, the TMD patient on average has (1) elevated resting EMG activity in mandibular postural muscles, (2) weak and/or asymmetrical functioning of their masticatory muscles, (3) temporalis over masseter dominance when exercising maximum voluntary clenching of the teeth, and (4) occlusion of the teeth that is not coincident with an optimal functioning neuromuscular masticatory system.

The data also demonstrate that TENS lowers the resting EMG activity and enables the identification of a neu-

Table 6
Comparison of the Natural Occlusion with Neuromuscular Occlusion Position of the Subjects Studied Before and After Orthosis Treatment (n=313)

| Condition | Condition prevalence | | Prevalence changes | |
|---------------------------------|---|--|--|--|
| | Natural occlusion at baseline teeth to teeth No. of subjects and % | Therapeutic occlusion at three mos. teeth to orthosis No. of subjects and % | No. of subjects w/changes after three mos. | % of subjects w/changes after three mos. |
| Not on neuromuscular trajectory | 264 (84.3%) | 24 (7.7%) | ↓ 240 | ↓ 90.9% |
| Over-closed (>2 mm) | 253 (82.1%) | 57 (18.9%) | ↓ 196 | ↓ 77.5% |
| Posterior displacement | 221 (71.8%) | 85 (28.2%) | ↓ 136 | ↓ 61.5% |
| Lateral displacement | 166 (53.9%) | 52 (17.2%) | ↓ 114 | ↓ 68.7% |

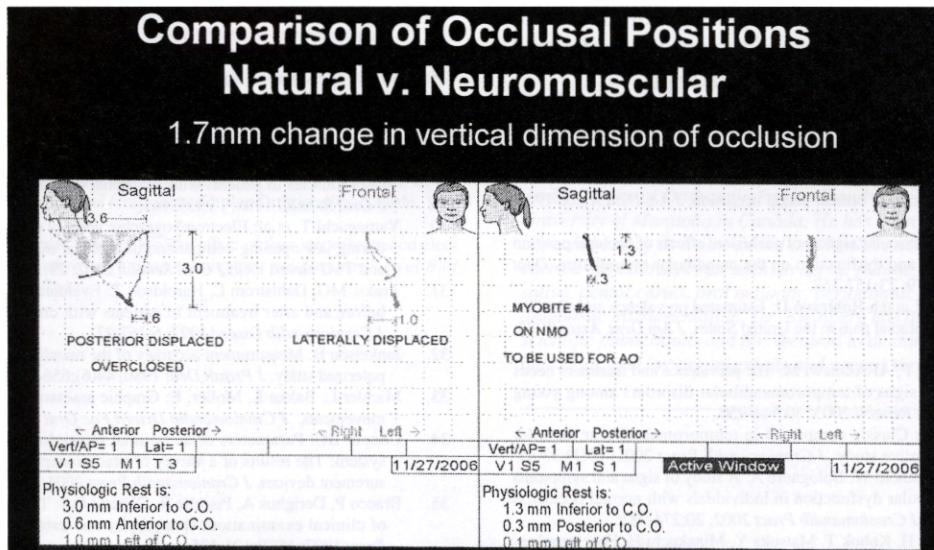


Figure 8

Comparison of occlusal positions after TENS natural (left) and neuromuscular (right). In these two sets of sagittal and frontal views, the TENS stimulated trajectory of mandibular movement from rest position creates an arc, which ends at the neuromuscular occlusion position (NMO). The patient then voluntarily closes to the natural occlusal position (CO) (left) and to the neuromuscular position (right). Left: natural occlusion is overclosed, posteriorly and laterally displaced vs. NMO. Right: with bite registration voluntary closure and TENS stimulated arc are coincident (CO=NMO). Vertical dimension has been increased 1.7 mm (measured anteriorly).

romuscularly directed therapeutic occlusion with significantly improved muscle function. They also show that treatment with a neuromuscular mandibular orthotic device enables functional parameters related to mandibular and masticatory function to be brought from a less to a more physiological state. This should be the goal of good treatment and this study has demonstrated how and why it should be done.

Earlier studies identified the parameters of a physiological state for the masticatory system.^{34,55} The data presented in the present study have demonstrated in 313 patients that a less physiological state can be moved to a more physiological state through the diagnostics and treatments used in this report.

Some of the patients who were treated successfully for TMD, as described herein, elected to undergo long-term treatment to perpetuate the altered neuromuscular state achieved. The treatment consisted of full or part-time use of removable orthotic appliances, dental restoration of certain posterior teeth, orthodontic treatment and in a very small number of cases, TM joint or orthognathic surgery.

Conclusion

TMD is generally associated with abnormalities of mandibular and masticatory muscle function. Dentists have traditionally evaluated patients relative to a func-

tional versus a dysfunctional state based on patients' subjective symptoms and a dentist's visual and palpable observations. By using precise computerized measuring devices, it was clear that objective rather than subjective measurements could be made to augment such diagnoses and as a consequence to carry out more complex and precise treatments.^{56,57}

The data presented in this study demonstrate that EMG and mandibular tracking devices in conjunction with low frequency, low voltage TENS can be effectively used to establish a neuromuscular physiological occlusion and through the use of fabricated neuromuscular occlusion orthotic appliances, relieve painful and unsatisfactory TMD conditions. This approach has demonstrated that drastic reduction in the magnitude and number of TMD symptoms can be achieved in a relatively short period of time.

This is consistent with the ultimate goal of therapeutic intervention, which is to bring patients from a less healthy to a more physiological and healthy state and to reduce the need for medications to control pain which at best can only be a temporary and incomplete solution.

Acknowledgement

The authors wish to acknowledge the programming and data analysis assistance of Gary Zaika, Ph.D. They also wish to acknowledge the excellent assistance of

Gayle Cooper in performing all patient computerized testing, Joan Bacigalupo for data input, and Pritpal Kainth in the preparation of this manuscript.

References

1. Jankelson B: Physiology of human dental occlusion. *J Am Dent Assoc* 1955; 50:664-680.
2. Jankelson B: Neuromuscular aspects of occlusion: effects of occlusal position on the physiology and dysfunction on the mandibular musculature. *Dent Clin North Am* 1979; 23:157-168.
3. Lipton JA, Ship JA, Larach-Robinson D: Estimated prevalence and distribution of reported orofacial pain in the United States. *J Am Dent Assoc* 1993; 124:115-121.
4. Nassif N, Al-Selleeh F, Al-Admawi M: The prevalence and treatment needs of symptoms and signs of temporomandibular disorders among young adult males. *J Oral Rehabil* 2003; 30:944-950.
5. Nassif, N, Talic, Y: Classic symptoms in temporomandibular disorder patients: a comparative study. *J Craniomandib Pract* 2001; 19(1):33-41.
6. Matsumoto M, Matsumoto W, Bolognese A: A study of signs and symptoms of temporomandibular dysfunction in individuals with normal occlusion and malocclusion. *J Craniomandib Pract* 2002; 20:274-281.
7. Kamisaka M, Yatani H, Kubok T, Matsuka Y, Minakuchi H: Four year longitudinal course of TMD symptoms in an adult population and the estimation of risk factors in relation to symptoms. *J Orofac Pain* 2000; 14:224-232.
8. Pedroni C, DeOliveria A, Guaratini M: Prevalence study of signs and symptoms of temporomandibular disorders in university students. *J Oral Rehabil* 2003; 30:283-289.
9. Carlsson G, Ege mark I, Magnusson T: Prediction of signs and symptoms of temporomandibular disorders: a 20 year follow-up study from childhood to adulthood. *Acta Odontol Scand* 2002; 60:180-185.
10. Magnusson T, Ege mark I, Carlsson G: A longitudinal epidemiologic study of signs and symptoms of temporomandibular disorders from 15-35 years of age. *J Orofac Pain* 2000; 14:310-319.
11. Cooper B, Kleinberg I: Examination of a large patient population for presence of symptoms and signs of temporomandibular disorders. *J Craniomandib Pract* 2007; 25(2):114-126.
12. Gremillion HA: The prevalence and etiology of temporomandibular disorders and orofacial pain. *Tex Dent J* 2000; 117:30-39.
13. Yemm R: The orderly recruitment of motor units of the masseter and temporalis muscles during voluntary contraction in man. *J Physiol (Lond)* 1977; 265:165-174.
14. Helkimo M, Carlsson G, Carnelli Y: Bite force in patients with functional disturbances of the masticatory system. *J Oral Rehabil* 1975; 2:397-406.
15. Milner-Brown HS: The relationship between the surface electromyography and muscular force. *J Physiol (Great Britain)* 1975; 246:549-569.
16. Bigland B, Lippold OCJ: The relationship between force, velocity and integrated activity in human muscles. *J Physiol* 1954; 123:214-224.
17. Ahlgren J, Owall AB: Muscle activity and chewing force: a polygraphic study of human mandibular movements. *Arch Oral Biol* 1981; 26:287-295, 547-553.
18. Molin C: Vertical isometric muscle forces of the mandible: a comparative study of subjects with and without manifest mandibular pain dysfunction syndrome. *Acta Odontol Scand* 1972; 30:485-499.
19. Ferrario V, Serrao G, Dellavia C, Caruso F, Sforza C: Relationship between the number of occlusal contacts and masticatory muscle activity in healthy young adults. *J Craniomandib Pract* 2002; 20(2):91-98.
20. Bakke M, Moller E: Distortion of maximal elevator activity by unilateral premature tooth contact. *Scand J Dent Res* 1980; 80:67-75.
21. Riise C, Sheikholeslam A: The influence of experimental interfering occlusal contacts on the activity of the anterior temporal and masseter muscles during mastication. *J Oral Rehabil* 1984; 11:325-333.
22. Jarabak JR: An electromyographic analysis of muscular and temporomandibular joint disturbances due to imbalances of occlusion. *Angle Orthodont* 1956; 26 (3):179-190.
23. Stegenga B, Broekhuijsen MI, DeBont LG, VanWilligen JD: Bite-force endurance in patients with temporomandibular joint osteoarthritis and internal derangement. *J Oral Rehabil* 1992; 19:639-647.
24. Gervais R, Fitzsimmons G, Thomas N: Masseter and temporalis electromyographic activity in asymptomatic subclinical and temporomandibular joint dysfunction patients. *J Craniomandib Pract* 1989; 7(1):52-57.
25. Burdette BH, Gale EN: Reliability of surface electromyography of the masseter and anterior temporal areas. *Arch Oral Biol* 1990; 35(9):747-751.
26. Buxbaum J, Mylinski N, Parente FR: Surface EMG reliability using special analysis. *J Oral Rehabil* 1996; 23:771-775.

27. Visser A, McCarroll RS, Oosting J, Naeije M: Masticatory electromyographic activity in healthy young adults and myogenous craniomandibular disorder patients. *J Oral Rehabil* 1994; 21:67-76.
28. Kotani H, Kawazoe Y, Hamada T, Yamata S: Quantitative electromyographic diagnosis of myofascial pain dysfunction syndrome. *J Prosth Dent* 1980; 43(4):450-456.
29. Sheikholeslam A, Holmgren K, Riise C: A clinical and electromyographic study of the long-term effects of an occlusal splint on the temporal and masseter muscles in patients with functional disorders and nocturnal bruxism. *J Oral Rehabil* 1986; 13:137-145.
30. Yamaguchi T, et al: Electromyographic activity of the jaw-closing muscles during jaw opening-comparison of cases of masseter muscle contracture and TMJ closed lock. *J Oral Rehabil* 2002; 29:1063-1068.
31. Tzakis MG, Dahlstrom L, Haroldson T: Evaluation of masticatory function before and after treatment in patients with craniomandibular disorders. *J Craniomandib Disord* 1992; 6:267-271.
32. Jankelson B: Measurement accuracy of the mandibular kinesiograph, a computerized study. *J Prosth Dent* 1980; 44(6):656-666.
33. Michler L, Bakke L, Moller, E: Graphic assessment of natural mandibular movements. *J Craniomandib Disord Fac Oral Pain* 1987; 1:97-114.
34. Cooper BC: Parameters of an optimal physiological state of masticatory system: The results of a survey of practitioners using computerized measurement devices. *J Craniomandib Pract* 2004; 22 (3):220-233.
35. Bracco P, Derigibus A, Pisetta R, Giaretta GA: TMJ clicking: a comparison of clinical examination, sonography and axiography. *J Craniomandib Pract* 1997; 15(2):121-126.
36. Ishigaki, S, Bessette R, Maruyama T: A clinical study of temporomandibular joint (TMJ) vibration in TMJ dysfunction patients. *J Craniomandib Pract* 1993; 11(1):7-13.
37. Heffez L, Blaustein D: Advances in sonography of the temporomandibular joint. *J Oral Surg Oral Med Oral Path* 1986; 62(5):486-495.
38. Gay T: The acoustical characteristics of the normal and abnormal temporomandibular joint. *J Oral Maxillofac Surg* 1987; 45:397-407.
39. Christensen, LV: Physics and the sounds produced by the temporomandibular joints (Part 1). *J Oral Rehabil* 1992; 19: 472-483. (Part 2) 1992; 19:615-627.
40. Tallents RH, Hatala M, Katzberg RW, Westesson PL: Temporomandibular joint sounds in asymptomatic volunteers. *J Prosth Dent* 1993; 69:298-304.
41. Elfving L, Helkimo M, Magnusson T: Prevalence of different temporomandibular joint sounds, with emphasis on disc displacement, in patients with temporomandibular disorders and controls. *Swed Dent J* 2002; 26:9-19.
42. Jankelson B, Radke, J: The Myomonitor: its use and abuse. *Quintessence Int Dent Digest* 1978; 9:35-39, 47-52.
43. Jankelson B, Sparks S, Crane P, Radke JC: Neural conduction of the Myomonitor stimulus: a quantitative analysis. *J Prosth Dent* 1975; 34(3):245-253.
44. Kamyszek G, Ketcham R, Garcia R Jr: Electromyographic evidence of reduced muscle activity when ULF-TENS is applied to the Vth and VIIth cranial nerves. *J Craniomandib Pract* 2001; 19(3):162-168.
45. Bazzotti L: Electromyography tension and frequency spectrum analysis at rest of some masticatory muscles, before and after TENS. *Electromyography Clin Neurophysiol* 1997; 37(6):365-378.
46. Eble OS, Jonas IE, Kappert HT: Transcutaneous electrical stimulation (TENS): Its short-term and long-term effects on the masticatory muscles. *J Orofac Orthoped* 2000; 61(2):100-111.
47. Burdette BH, Gale EN: The effects of treatment on masticatory muscle activity and mandibular posture in Myofascial pain-dysfunction patients. *J Dent Res* 1988; 67(8):1126-1130.
48. Michelotti A, Farella M, Vollaro S, Martina, R: Mandibular rest position and electrical activity of the masticatory muscles. *J Prosth Dent* 1997; 78:48-53.
49. Konchak PA, ThomasNR, Lanigan, DT, Devon RM: Freeway space measurement using mandibular kinesiograph and EMG before and after TENS. *Angle Orthodont* 1998; 58(4):343-350.
50. Jankelson RR: Effect of vertical and horizontal variants on the resting activity of masticatory muscles. *Anthology of Craniomandibular Orthopedics*, Vol IV, Coy, R, ed. International College of Craniomandibular Orthopedics. Seattle, WA 1997:69-76.
51. Wessberg GA, Epker BN, Elliot AC: Comparison of mandibular rest positions induced by phonetics, transcutaneous electrical stimulation and masticatory electromyography. *J Prosth Dent* 1983; 49(1):100-105.
52. Miralles R, Dodds C, Palazzi C, Jaramillo C, Quezada V, Ormeno G, Vellegas R: Vertical dimension Part I: comparison of clinical freeway space. *J Craniomandib Pract* 2001; 19(4):230-236.
53. Mann A, Miralles R, Cumsille F: Influence of vertical dimension on masseter muscle electromyographic activity in patients with mandibular dysfunction. *J Prosth Dent* 1985; 53(2):243-247.

54. Louis I, Sheikholeslam R, Moller B: Postural activity in subjects with functional disorders of the chewing apparatus. *Scand J Dent Res* 1970; 78: 404-410.
55. Ferrario VF, Sforza C, Mani A Jr, D'Addona A, Barbin E: Electromyographic evaluation of human masticatory muscles in normal young people. Statistical evaluation of reference values for clinical applications. *J Oral Rehabil* 1993; 20(30):271-280.
56. Cooper BC: *Scientific rationale for biomedical instrumentation: neuromuscular dentistry in the next millennium Anthology*, Vol V. Hickman, D, ed. International College of Craniomandibular Orthopedics, Seattle, WA 1999:11-30.
57. Hickman D, Cramer R, Stauber W: The effect of four jaw relations on electromyographic activity in human masticatory muscles. *Arch Oral Biol* 1993; 38(3): 261-264.

Dr. Israel Kleinberg is a distinguished professor and chairman of the Department of Oral Biology and Pathology at State University of New York at Stony Brook School of Dental Medicine. He holds a D.D.S. from the University of Toronto, a Ph.D. in biochemistry and physiology from the University of Durham in England, and a D.Sc. degree from the University of Manitoba in Canada. He has been instrumental in pioneering oral biology as a new dental and health science discipline. He has carried out extensive research on dental plaque, microbial ecology, saliva, dental caries, oral malodor, periodontal disease formation, and diagnostic instrumentation. Dr. Kleinberg has authored more than 300 scientific publications and has lectured to dental, medical, scientific, industrial, and lay organizations and groups throughout the world.
